

## Repair of Middle Third Subcrestal Root Perforation with Mineral Trioxide Aggregate - Case Report

Dr. Marsrat Kapadwala<sup>1</sup>, Dr. Geeta Asthana<sup>2</sup>, Dr. Shaveta Bhargava<sup>3</sup>,  
Dr. Girish Parmar<sup>4</sup>

<sup>1</sup>(PgStudent, Department Of Conservative Dentistry And Endodontics, Govt. Dental College/ Gujarat University, Ahmedabad India)

<sup>2</sup>(Professor, Department Of Conservative Dentistry And Endodontics, Govt. Dental College/ Gujarat University, Ahmedabad India)

<sup>3</sup>(PgStudent, Department Of Conservative Dentistry And Endodontics, Govt. Dental College/ Gujarat University, Ahmedabad India)

<sup>4</sup>(Professor And Head, Department Of Conservative Dentistry And Endodontics, Govt. Dental College/ Gujarat University, Ahmedabad India)

---

**Abstract :** Perforations are the undesirable complications that can occur during root canal treatment. Cervical perforations, below the crestal bone (subcrestal) has poor prognosis after repair. Inadequate sealing capacity and lack of biocompatibility of the repair materials has been a contributing factor to the poor outcome of repair procedures. Newer biocompatible and bioactive materials have provided more predictable results after sealing of perforation. It has been concluded that MTA provides an effective seal of perforations and can be considered a potential repair material enhancing the prognosis of perforated teeth. This article presents case report of iatrogenic middle third root perforation repaired successfully with MTA without internal matrix with 12 months follow up.

**Keywords:** Iatrogenic Perforation, Mineral Trioxide Aggregate, Subcrestal Perforation

---

### I. Introduction

For any dentist, the moment of regret is any procedural misadventures- one of the most aggravating of which is the operative perforation. Perforations are undesirable complications and unfortunate incidents that can occur during pulp space therapy.

The purpose for repair of the perforation is to seal the artificial communication between the endodontic space and the periradicular tissue to prevent alveolar bone resorption and damage to the periodontal ligament. Several factors influence the prognosis of perforation repair such as time, size and location of the perforation.

In recent times interest, has centered upon use of Mineral Trioxide Aggregate (MTA) which has fulfilled all the requirements of an ideal material such as biocompatibility, bioactivity and superior seal when compared to Amalgam, IRM and Super EBA.

Various physical and biological property studies of the MTA, have demonstrated repair of the periodontium and new cementum formation over the material <sup>[1],[2]</sup>.

Thus, it may be suitable for closing the communication between the pulp and the underlying periodontal tissues. This case report supports this hypothesis.

### II. Case Report

A 15 years old male patient was referred to the Department of Conservative dentistry and endodontics with a chief complaint of episodes of pain in the right lower back tooth region since 4 months. Patient gave history of previous root canal treatment in the same tooth 3 months before.

Upon clinical examination, we observed open pulp chamber in lower right first molar with visible perforation on distal wall of distal root associated with profuse bleeding. There was pain on percussion with 5 mm deep periodontal pocket on the distal aspect of tooth. On preoperative radiograph, subcrestal perforation as well as bone loss of distal marginal ridge was detected (fig 1-A). Radiograph was taken with no 10k files, but it was in to the perforation on distal aspect (fig 1-B). Then after, original canal in distal root was identified and the working length was determined radiographically (fig 1-C). The mesial and the distal canals were cleaned and shaped using ProTaper Next Rotary File Systems (Dentsply, Maillefer, Switzerland) and irrigation was done with 5.25% sodium hypochlorite and final rinse was done with 2% Chlorhexidine (Dentochlor, Ammdent) with intermediate solution of saline. Ideally attempt should be made to obturate the canal apical to the perforation with guttapercha and sealer and seal the rest of the canal with MTA but here the defect was large and the canal could not be definitively dried, so the perforation was first repaired before the obturation. To prevent obstructing

the root canal space during repair procedures guttapercha cones were inserted in to the root canals (fig 1-D). The perforation was sealed with MTA- sterile saline paste (ProRoot MTA Dental Tulsa; Dentsply, DeTrey Konstanz, Germany) mixed in a 3:1 proportion (Fig 2-E). MTA was applied with the help of a MTA carrier, a damp cotton pellet was then placed in the pulp chamber to produce a humid environment for MTA to set, and the tooth was temporary filled with Cavit-G (3M ESPE, St. Paul, Minnesota, USA) temporary restorative material (fig 2-F). The patient was recalled after 24 hours. He had no symptoms or signs. Temporary sealing materials and wet cotton pellet were removed and the hardness of the MTA was gently tested with an operator explorer. The cones were removed and canals were copiously irrigated, with NaOCL and saline and the root canal system was obturated (fig 2-G). Final restoration of composite (Tetricceram, IvoclarVivadent, Schaan, Liechtenstein) was placed immediately after guttapercha sealing, to prevent any further coronal leakage (fig 2-H, I). 3 months (fig 3-J) and 12 months follow up was done (fig 3-K, L, M).

### III. DISCUSSION

Often, the cause of perforation which occurs in 2-12% of endodontically treated teeth is iatrogenic as a result of misaligned use of rotary burs during endodontic access preparation, search for root canal orifices in curved or calcified canals or may be inappropriate post space preparation.<sup>[3], [4]</sup> There may be non-iatrogenic causes like resorption and caries.<sup>[5]</sup>

Root perforations may adversely affect the prognosis of teeth. Bacterial infection emanating either from the root canal or the periodontal tissues, prevents healing and brings about inflammatory sequels where exposure of the supporting tissues is present. Down-growth of gingival epithelium at the perforation site can emerge, especially when it occurs in the crestal area by lateral perforation<sup>[6]</sup>.

Regardless of cause, for the best prognosis a perforation should be repaired as soon as possible to discourage further loss of epithelium and prevent sulcular breakdown<sup>[7]</sup>. Its size and location represents another important factors in determining the success of the repair procedure. Large perforation (larger than #20 endodontic instrument) is associated with poor prognosis. In coronal, crestal and apical third perforation, crestal perforation has poor prognosis because perforation at this level threatens the sulcular attachment and has direct communication with oral cavity via pocket formation as in our case.

Two main challenges a clinician faces when attempting to repair a perforation are hemostasis and controlled placement of sealing material. First was achieved with successive placement of 1:80,000 adrenaline containing 2% local anaesthesia and, later with MTA.

some authors suggest the use of internal matrix to avoid the extrusion of the sealing material and consequent periradicular tissue inflammation<sup>[8]</sup>. Arens and Torabinejad<sup>[9]</sup> observed better results when furcal perforations were repaired by MTA without internal matrix as opposed to MTA with internal matrix. So, in this case MTA was used without internal matrix.

It can be considered clinical and radiographically successful, because, at the 3-month recall, healing was evident in the perforation site, and no fistula, edema, or pain, were reported by the patient. (fig 2-J)

After 12 months, the tooth remained asymptomatic and on clinical examination probing depth which was 5 mm initially, decreased to 2 mm. Radiographic examination showed signs of normality, marginal bone formation on distal margin of affected tooth and the patient was also satisfied. (fig 3-K, L, M)

figures

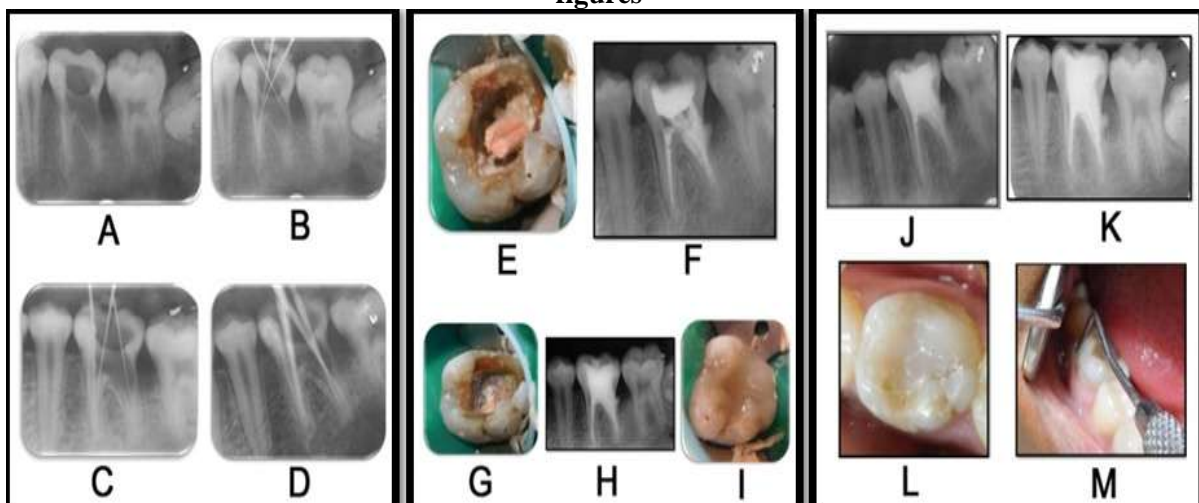


Figure 1

Figure 2

Figure 3

Figure 01- A-preoperative, B- file inserted in to the perforation, C- working length determination, D-master cone selection. Figure 02- E- MTA placement at the perforation site, F- MTA with cotton plug and temporary restoration, G- post obturation, H & I- post operative after composite restoration  
Figure 03- J- 3 months follow up, K-L-M -12 months follow up photographs

#### **IV. Conclusion**

An excellent initial clinical and radiographical examination, careful consideration of size, level and the time of perforation provides a better prediction of prognosis of perforation repair. Nevertheless, advances in technologies have also provided for more controllable and better treatment outcomes, either surgically or non-surgically.

#### **References**

- [1]. Torabinejad M, Hong CU, McDonald F, Pitt Ford TR. Physical and chemical properties of a new root-end filling material. *J Endod* 1995; 21:349–53.
- [2]. Pitt ford TR, Torabinejad M, McKendry DJ, Hong CU, Kariyawasam SP. Use of mineral trioxide aggregate for repair of furcal perforations. *Oral Surg Oral Med Oral Pathol Oral Radiol Endod* 1995; 79:756-63
- [3]. Kvinnsland I, Oswald RJ, Halse A, Gronningsaeter AG. A clinical and roentgenological study of 55 cases of root perforation. *Int Endod J* 1989; 22: 75–84
- [4]. Seltzer S, Bender IB, Smith J, Freedman I, Nazimov H. Endodontic failures – an analysis based on clinical, roentgenographic, and histologic findings. *Oral Surg Oral Med Oral Pathol* 1967; 23: 500–530.
- [5]. Sinai IH. Endodontic perforations: their prognosis and treatment. *J Am Dent Assoc* 1977; 95: 90–95.
- [6]. Tsesis I, Fuss Z. Diagnosis and Treatment of accidental root perforations. *Endodontic Topics* 2006; 13: 95-107
- [7]. Cohen S, Liewehr F. Diagnostic procedures. In: Cohen S, Burns RC, eds. *Pathways of the Pulp*, 8<sup>th</sup> edn. St Louis, MO: CV Mosby, 2002: 917-929.
- [8]. Rafter M, Baker M, Alves M, Daniel J, Remeikis N. Evaluation of healing with use of an internal matrix to repair furcation perforations. *Int Endod J* 2002; 35:775– 83.
- [9]. Arens DE, Torabinejad M. Repair of furcal perforations with mineral trioxide aggregate: two case reports. *Oral Surg Oral Med Oral Pathol Oral Radiol Endod* 1996; 82: 84–8.